



**PATIENT**

Jeri Raleigh

**SPECIES**

Feline

**BREED**

DSH

**SEX**

Female Spayed

**AGE**

10.4 years

**WEIGHT**

12.56lbs

**INTERPRETED BY**

Maggie Machen Lamy,  
DVM, DACVIM  
(Cardiology)

**IMAGING PERFORMED BY**

Melinda Persson, DVM

**HOSPITAL NAME**

At Home Veterinary

**REFERRING VET**

Dr. Melinda Persson

**INVOICE**

47665

**DATE**

4/23/26

**PRESENTING CLINICAL SIGNS**

History: Recheck echo. Normal BNP (10/2025). BP: 165mmHg.  
-Pertinent previous echo findings (10/2025 MML): Focal basilar septal hypertrophy (0.71cm); remainder NSF.

**ECHOCARDIOGRAM FINDINGS**

2D, m-mode, color flow and doppler imaging is available. Significant focal basilar septal hypertrophy is noted. The free wall is normal. There is a diffusely hyperechoic endocardium consistent with fibrosis. Mild symmetric papillary muscle hypertrophy and remodeling. The right ventricle is subjectively normal in size and morphology. There is no left atrial enlargement present. No right atrial enlargement present. Normal RVOT velocity. Trace TR. Normal LVOT velocity. There is no obvious systolic anterior motion (SAM) of the mitral valve present. No MR. No significant AI or PI. There is no pericardial effusion noted. No pleural effusion appreciated. No obvious cardiac tumors.

**CARDIAC CHART**

FELINE CARDIAC PARAMETERS	BODY WEIGHT (kg)	HR (BPM)	IVSd (cm) (Moise, Pipers)	LVIDd (cm) (Moise, Pipers)	LVWd (cm) (Moise, Pipers)	FS (%)	EF (%)
NORMAL PARAMETER	-----	150-240	0.35-0.55	<2 (mean 1.5)	3.5-0.55	35-67	80-100
PATIENT	5.7	NM	0.70	1.2	0.47	52	82
FELINE CARDIAC PARAMETERS	LA/AO (Boon)	LA/AO HEART BASE (Swe) (Abbott)	LA 2D short axis Base view (cm) (Abbott)		LVOT VEL (m/s)	RVOT VEL (m/s)	E max (m/s)
NORMAL	<1.5	<1.3	<1.2		<1.6	<1.3	<0.9
PATIENT	NM	1.2	1.1		1.0	0.9	NM

*\*Note: All measurements based upon multi-modal images and methods. An average value is reported.*  
Adapted from June Boon, Veterinary Echocardiography, 1998  
Abbott J & MacLean H JVIM 2006;20: 111-119, Moise et al. Am J Vet Res 47:1476, 1986. Pipers et al. Am J Vet Res 40:882, 1979.

**INTERPRETATION OF THE FINDINGS & FURTHER RECOMMENDATIONS**

No change compared to the prior evaluation. The focal septal hypertrophy is similar to previous, while the remainder of the LV measures normal. The LA is normal is no additional issues are seen.

Given these findings, no medications are indicated.

Prognosis remains guarded; however, a lack of progression is always a good sign. Close monitoring for progressive LA dilation in the future will help determine long term outcome.



## PATIENT

Jeri Raleigh

## SPECIES

Feline

## BREED

DSH

## SEX

Female Spayed

## AGE

10.4 years

## WEIGHT

12.56lbs

## INTERPRETED BY

Maggie Machen Lamy,  
DVM, DACVIM  
(Cardiology)

## IMAGING PERFORMED BY

Melinda Persson, DVM

## HOSPITAL NAME

At Home Veterinary

## REFERRING VET

Dr. Melinda Persson

## INVOICE

47665

## DATE

4/23/26

Monitor at home for any respiratory issues or signs of blood clot events (neurologic change, paralysis, etc.).

Anesthetic risk is considered mildly elevated; however, judicious fluid administration is advised if needed with careful monitoring to screen for fluid overload. A reasonable protocol includes opioid/benzodiazepine premedication, propofol induction, isoflurane maintenance. Avoid ketamine, telazol, acepromazine and Dexdomitor. Additionally, drugs that stimulate heart rate should be avoided unless clinically necessary (glycopyrrolate, atropine).

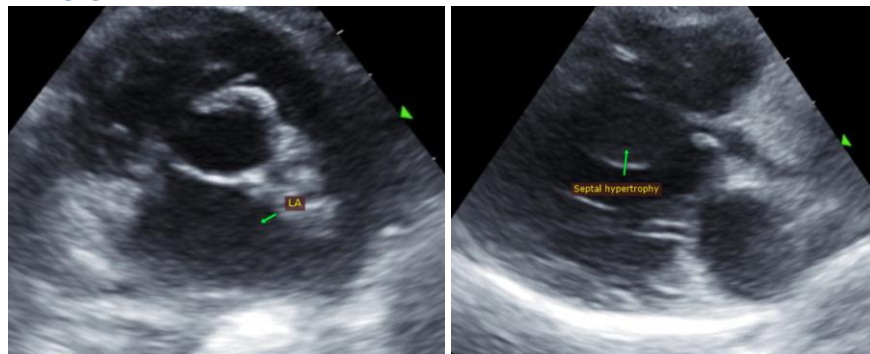
Risk for complication with steroid or fluid use typically follows LA dilation, which in this case is mildly elevated. If needed, monitoring of RR/RE is advised particularly in the initiation phase.

## PLAN

A screening blood pressure and T4 are recommended every 6 months lifelong.

A recheck echocardiogram is recommended in 6-12 months to assess for progression, sooner if any issues arise in the interim.

## IMAGES



**The information and recommendations provided are based on the images presented by the referring veterinarian. No evaluation can be communicated regarding pathology that was not visible in the image/video clips provided.**

Thank you for this referral. This report was generated using transcription software, and minor dictation errors may be present. If the clinical or image interpretation does not parallel your findings or if I can be of any further assistance, please contact me.

**Maggie Machen Lamy, DVM**  
**Diplomate of the American College of Veterinary Internal Medicine (Cardiology)**  
info@sonopath.com